

## Research Article

# Premature Greying of Hair and Role of Oiling in Indian Perspective

Raman Mahajan<sup>1</sup>, Richa Nagpal<sup>1</sup>, Parul Chojer<sup>1</sup>, Mahajan BB<sup>1</sup>

<sup>1</sup> Department of Dermatology, Government Medical College, 174-A Subhash Nagar, Rohtak, Haryana, India

**Copyright:** © 2017 Richa Nagpal, et al. This is an open-access article distributed under the terms of the Creative Commons Attribution License, which permits unrestricted use, distribution, and reproduction in any medium, provided the original author and source are credited.

## Abstract

Premature Greying is the term used when hair turn grey prematurely. Though greying of hair is a natural process, yet in the modern era of cosmetological revolution, it has assumed a lot of aesthetic relevance, especially premature hair greying. Countless products are flooding the market everyday like, hair oils, shampoos, conditioners, gels and hair dyes which claim to slow/ revert premature hair greying but all these provide only temporary relief, if any. There are various known causes of premature hair greying like Excessive prolonged stress, Thyroid Deficiencies, Excessive intake of tea, coffee and alcohol, fried foods, spices, sour and acidic foods, Deficiency of nutrients esp. copper reduces melanin production, Deficiency of B 12 & Biotin and hereditary causes. Common hair oils used in India include Coconut oil, Amla oil (Indian Gooseberry), Mustard oil, Olive oil, Almond oil and Mineral oils, out of which Coconut oil is the most commonly used. Coconut oil owing to its low molecular weight and high affinity for hair proteins, having the capacity to penetrate the cuticle and displacing the air which has replaced the melanin, may have a role in not only delaying the premature greying of hair, but also giving cosmetic acceptability to the hair by making them appear less grey.

**Keywords:** Premature greying, Oiling, Canities, Melanogenesis

*"It is not by the Grey of the hair that one knows the age of the heart".*

Edward G Bulwar

Greying of hair is a physiologic process that occurs in both men and women. Though greying of hair is a natural process, yet in the modern era of cosmetological revolution, it has assumed a lot of aesthetic relevance, especially premature hair greying. Black, thick and shiny hair are not only sign of youthfulness and good health but are also cosmetically appealing.

## Introduction

Greying of hair is usually a manifestation of the ageing process. The average age of onset of hair greying is 34 to 44 years depending on race, with an estimated 50% of men and women being 50% grey by 50 years of age [1]. The beard and moustache areas commonly grey before the scalp or body hair. Greying over temporal region of scalp precedes crown, which is followed by occipital area [1,2].

Hairs are said to grey prematurely only if greying occurs before the age of 20 years in Whites, 25 years in Asians and 30 years in Africans [3]. Caucasian people will begin to grey in their mid-thirties, African-American people can retain their original hair colour until their mid-forties, Asian people begin greying in their late thirties, however as compared to South Indian population, North Indians begin to grey in their early thirties. Premature greying of hairs has significant effect on self-esteem and social acceptance of the individual as it is viewed as a sign of old age and loss of health and vigor.

Hair oiling has been in practice since time immemorial. Various hair oils being used in India are mustard oil, mineral oil, olive oil, coconut oil, amla oil, almond oil; with mustard oil being predominantly used in north India and coconut oil in southern parts of country. The hair care and cosmetic industry has provided us with plethora of products to beautify, enhance, strengthen and 'nourish' our tresses. Most of the products work at the cuticle level of the exposed hair shaft. Countless products are flooding the market everyday like, hair oils, shampoos, conditioners, gels and hair dyes which claim to slow/ revert premature hair greying but all these provide only temporary

relief, if any.

## Etiopathogenesis

### Biology of hair pigmentation

In humans, hair color is determined by melanin incorporation into the hair shaft, which is formed by melanocytes situated in the hair bulb epithelium around the upper half of the dermal papilla amongst cells destined to form hair cortex. Hair bulb melanocytes are more melanogenic than epidermal melanocytes. The human hair follicles contain two types of melanins: the black-brown pigment eumelanins mainly present in black and brown hair and the yellow or red pheomelanins in auburn and blonde hair [3]. Density of melanocytes is much greater than in the epidermis (approximately one melanocytes to four basal keratinocytes in the upper hair bulb compared with ratio of 1:36 in the basal layer of epidermis). (Figure 1) Hair follicle melanogenesis is under cyclical control and tightly coupled to the hair growth cycle in contrast to epidermal melanogenesis that is continuous.

Melanocytic activity is closely associated with hair cycle. Melanocyte stem cells are activated and their offsprings migrate into developing hair bulb in early anagen phase. The close anatomical and functional association of hair bulb melanocytes with cells to which pigment is donated, cells destined to form the hair cortex, suggests that interaction between these two types of cells has a key role in regulation of pigmentary activity.

Hair growth has three periods: hair shaft production (anagen), brief apoptosis drive regression phase when the lower two-thirds of

**\*Corresponding author:** Richa Nagpal, 174-A Subhash Nagar, Rohtak, Haryana, India, 124001, Tel: +91 8146782991; Fax: +91 8146782991; E-mail: dr.richanagpal@gmail.com

**Received:** November 23, 2017; **Accepted:** December 14, 2017; **Published:** December 18, 2017

hair follicle are resorbed (catagen), and a relatively quiescent period (telogen). Melanocytes in the hair bulb retract their melanocytes and shut down melanogenesis towards the end of anagen. Simultaneously there is a decline in the activity of three main melanogenic enzymes: tyrosinase, gp75, and dopachrome tautomerase [3]. This occurs a few days before the cessation of keratinocyte proliferation resulting in the pigment-free proximal ends of shed telogen hair. During catagen, hair apoptosis occurs and a quiescent hair follicle much smaller in size is left in telogen. Melanogenic activity restarts during early anagen with the reconstruction of the follicular melanin unit. Tyrosinase activity becomes apparent during anagen III, pigment transfer from hair bulb melanocytes to cortical keratinocytes is initiated during anagen IV and active melanogenesis continues throughout anagen V and VI, ceasing with the onset of catagen [3-6]. Anagen usually persists for 3-5 years, and these follicles extrude the hair fiber at a rate of approximately 1 cm per month [7]. Melanocytes are present in two compartments of the hair follicle: in the anagen hair bulb, where they transfer pigment to cells that will form the hair cortex, and in the outer root sheath (ORS).

**Before understanding the greying on hair, studying its etiopathogenesis is very important**

#### Greying of hair

Mechanism of greying has not been determined with certainty. Grey or white hair-sometimes colloquially called "salt and pepper" hair is due to a lack of pigmentation and melanin which is most likely due to exhaustion of melanocyte stem cell reservoir. An alternate explanation is that the melanocytes are depleted as a result of the accumulation of hydrogen peroxide in the hair follicle. The clear hairs appear as grey or white because of the light reflected from the hollow shaft filled with air, which has replaced the melanin.

Premature greying or canities may reflect a genetically regulated early exhaustion of the melanocyte reservoir's seeding potential or some defect in cell activation/ migration compounded by environmental factors, inflammation, or psychological stress. Nishimura et al. suggested that loss of melanocyte stem cells can be observed and temporarily precedes the loss of differentiated melanocytes in the hair matrix. This incomplete maintenance of melanocyte stem cells appears to cause physiologic hair greying through loss of differentiated progeny with aging [8-10]. The progression of greying is compounded by the fact that with advancing age more hair follicles remain for longer duration in the resting phase (telogen) [3,11,12].

Premature canities may appear alone without any underlying pathology as an autosomal dominant condition occurring before 20 years of age. It may also occur in association with certain organ-specific autoimmune disorders like pernicious anemia, hyper- or hypothyroidism, and as part of various premature aging syndromes (e.g. progeria and pangeria) and atopic diathesis [13,14]. Reversible hypopigmentation of hair has also been noted in association with nutritional deficiencies like chronic protein loss (due to kwashiorkor, nephrosis, celiac disease, and other causes of malabsorption), severe iron deficiency and copper deficiency [13,15]. Serum copper was significantly lower in 66 patients with premature canities, as compared to normal controls (66) in one study. Binding of copper ions to the enzyme tyrosinase, which is essential for enzyme activity and thus the process of melanogenesis, may possibly be affected in patients with premature canities and low serum copper levels [16]. Other causes implicated include stress, and administration of certain drugs including chloroquine, mephenesin, phenylthiourea, triparanol, fluorobutyrophenone, dixyrazine, the epidermal growth factor receptor inhibitor imatinib and interferon - alpha, and use of certain chemicals (medicated oils) and topically applied agents

like dithranol, chrysarobin, resorcin, prostaglandin F2 alpha (PGF2 alpha) analogs [13,17,18]. Excessive prolonged stress: "genotoxic stress" damages melanin producing stem cells. Premature Greying has also been reported in patients with HIV infection, cystic fibrosis, and Hodgkin's lymphoma [17,19,20].

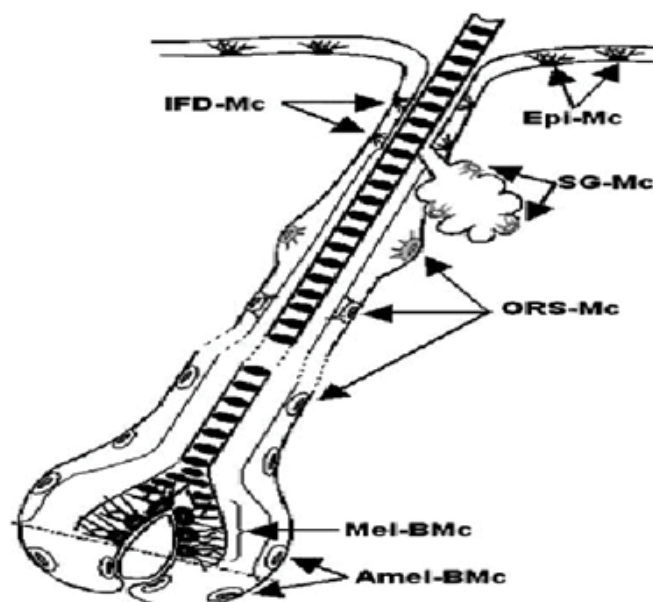
Smoking was reported to be significantly correlated with hair Greying, and impairment of stem cell regenerative capacity with substance abuse was postulated to lead to Greying in a single case report [21,22].

Hair lightening can be divided into roughly seven stages from the darkest to the lightest/whitest.

A natural black hair will go from:

Black -> Brown -> Red -> Red-gold -> Gold -> Yellow -> Pale Yellow -> Silvery White.

**Figure 1**



IFD-Mc- Infundibular melanocytes  
Epi-Mc- Epidermal melanocytes  
SG-Mc- Sebaceous gland melanocytes  
ORS-Mc- Outer root sheath melanocytes  
Mel-BMc- Melanogenic bulbar melanocytes  
Amel-BMc- Amelanotic bulbar melanocytes

**Figure 1:** showing location of melanocytes in hair follicle.

#### Clinical Features

The onset and progression of greying correlate very closely with chronological aging and at least a few Grey hair are found in all individuals regardless of gender or race by 60 years of age [23]. In contrast to aging of our skin, premature greying may not be hastened by cumulative photodamage [8]. In men, greying usually begins at the temples and in the sideburns. Later it spreads to the vertex and the remainder of the scalp, affecting the occiput last. Women usually start greying around the perimeter of the hairline. The rate at which an individual turns Grey depends on genetics. Beard and body hair are affected later. Chest, pubic, and axillary hair may remain pigmented even in old age [24]. Jo et al. Reported temporal and occipital areas to be more commonly involved in men than in women, with greying usually starting in the temporal area in men but in the frontal area in women. Initially involved scalp regions were also different depending on age of onset; that is, parietal or occipital area was more involved at onset in early-onset group, whereas frontal area was more involved initially in late-onset group. Early onset did not mean faster progress.

Rather, the extent of greyness sharply increased after the fifth decade regardless of age at onset [21].

Greying of hair is usually progressive and permanent, but there are occasional reports of spontaneous repigmentation of Grey hair, and partial, spontaneous reversal of canities may occur during the early stages of canities, whereby melanogenesis in de-activated bulbar melanocytes is re-started during anagen of the same hair growth cycle [3]. Finlay et al. reported that the perception of hair color is affected by the physical characteristics of the hair shaft and may bear little relationship to the true chromacities of the shaft [25]. It has been suggested that increased reflection of light may occur on cell interfaces and islets of interfibrillary matrix [13]. The white color of canities is an optical effect, that is, the reflection/ refraction of incident light masks the intrinsic pale-yellow color of hair keratin [3]. True Grey hair are not common till old age and need to be differentiated from white hair [26]. White hair have no melanocytes or pigmentation, while Grey hair has some persisting color with aberrantly distributed melanosomes. White hair usually affects only the scalp and about 5% of individuals will have whitening of hair by the fourth decade of life [23]. Grey hair is believed to be coarser, stiffer, and less manageable than pigmented hair [27,28]. Gao et al. reported that Grey hair undergoes more severe UV damage and needs more UV protection than dark brown hair [29]. Grey hair often fails to hold a temporary or permanent set, and is more resistant to incorporating artificial color possibly due to changes in the underlying substructure of the hair fiber. Melanin transfer possibly decreases keratinocyte turnover and increases keratinocyte terminal differentiation.

### Oiling- Indian Perspective

Common hair oils used in India include Coconut oil, Amla oil (Indian Gooseberry), Mustard oil, Olive oil, Almond oil and Mineral oils.

Mustard oil has Monounsaturated Fatty acids (60%- Oleic acid), rich in Omega 3 and 6 fatty acids. It has Antifungal and Antibacterial Properties due to the presence of Allyl Isothiocyanate. Mustard oil usage practices are quite popular in North India. However, the same compound from the past two decades has led to irritation and photosensitization.

Sunflower oil, due to its bulky structure owing to the presence of double bonds, does not penetrate the fiber.

Cinnamic oil obtained from bark of Cinnamin herb has antibacterial, antifungal and healing properties. However, just like mustard oil it can also cause Irritant and Allergic Contact dermatitis due to presence of Cinnamaldehyde.

Mineral oil, being a hydrocarbon, has no affinity for proteins and therefore is not able to penetrate.

Coconut oil is rich in saturated fatty acids (70%) and Vitamin E. Coconut oil, being a triglyceride of lauric acid (principal fatty acid), has a high affinity for hair proteins and because of its low molecular weight and straight linear chain, is able to penetrate inside the hair shaft. Due to high affinity for hair proteins, only coconut oil reduces protein loss remarkably from both undamaged and damaged hair. Coconut oil prevents swelling of hair. Since the process of swelling and shrinking of hair is an important cause of hair damage by hygral fatigue, coconut oil may protect hair from damage as well [30].

Coconut oil massage also improves the blood circulation of the scalp that gradually restores hair color & prevents further greying of hair, thus, delays the greying process and strengthens the hair and promotes growth. Additionally, it has soothing and cooling properties. At present, despite all the available hair products claiming to prevent premature hair greying, they have no permanent role to play. Only coconut oil, which is a saturated oil, applied topically, has the ability

to penetrate the hair cuticle and preventing the loss of protein may have a role in delaying the premature greying and causing the hair to appear less grey as it displaces the air entrapped within the shaft, which is the main culprit in giving the hair its grey color.

### Conclusion

The hair cosmetic industry has undergone a revolutionary change over the last two decades.

The focus has dramatically veered from merely cleaning to repair, increasing the tensile strength, reducing oxidative damage, and stimulating growth. Various products are available in the market for reversing and treating the greying of hair.

Indian perspective on oiling reveals that despite of using mustard oils, no significant effects on Greying of hair is seen in North Indians. South Indians grey later and have better hair quality than their counterparts in North India where Greying begins in their early thirties where mustard oil application is prevalent. So, once mistakenly thought to be bad because of its high saturated fat content, coconut oil owing to its low molecular weight and high affinity for hair proteins, having the capacity to penetrate the cuticle and displacing the air which has replaced the melanin, may have a role in not only delaying the premature greying of hair, but also giving cosmetic acceptability to the hair by making them appear less grey. The differences have widely been ascribed to the widespread use of coconut oil, both in cooking and topically for hair and skin.

### References

1. Keogh EV, Walsh RJ (1965) Rate of greying of human hair. *Nature* 207: 877-878. [\[crossref\]](#)
2. Wood JM, Jimbow K, Boissy RE, Slominski A, Plonka PM, et al. (1999) What's the use of generating melanin? *Exp Dermatol* 8: 153-164. [\[crossref\]](#)
3. Tobin DJ, Paus R (2001) Graying: gerontology of the hair follicle pigmentary unit. *Exp Gerontol* 36: 29-54. [\[crossref\]](#)
4. Tobin DJ, Bystryn JC (1996) Different populations of melanocytes are present in hair follicles and epidermis. *Pigment Cell Res* 9: 304-310.
5. Horikawa T, Norris DA, Johnson TW, Zekman T, Dunscomb N, et al. (1996) DOPA-negative melanocytes in the outer root sheath of human hair follicles express premelanosomal antigens but not a melanosomal antigen or the melanosome-associated glycoproteins tyrosinase, TRP-1, and TRP-2. *J Invest Dermatol* 106: 28-35. [\[crossref\]](#)
6. Shaffrali FC, McDonagh AJ, Messenger AG (2002) Hair darkening in porphyria cutanea tarda. *Br J Dermatol* 146: 325-329. [\[crossref\]](#)
7. Stenn KS, Paus R (2001) Controls of hair follicle cycling. *Physiol Rev* 81: 449-494. [\[crossref\]](#)
8. Tobin DJ (2009) Aging of the hair follicle pigmentation system. *Int J Trichology* 1: 83-93. [\[crossref\]](#)
9. SUNDERLAND E (1956) Hair-colour variation in the United Kingdom. *Ann Hum Genet* 20: 312-333. [\[crossref\]](#)
10. Nishimura EK, Granter SR, Fisher DE (2005) Mechanisms of hair graying: incomplete melanocyte stem cell maintenance in the niche. *Science* 307: 720-724. [\[crossref\]](#)
11. Peters EM, Imfeld D, Gräub R (2011) Graying of the human hair follicle. *J Cosmet Sci* 62: 121-125. [\[crossref\]](#)
12. Arck PC, Overall R, Spatz K, Liezman C, Handjiski B, et al. (2006) Towards a "free radical theory of Greying": Melanocyte apoptosis in the aging human hair follicle is an indicator of oxidative stress induced tissue damage. *FASEB J* 20: 1567-1569.
13. Dawber RP, Gummer CL (1997) The colour of the hair. In: Dawber R editor. *Diseases of the hair and scalp*. 3rd ed. Oxford: Blackwell Science; p. 397-416.
14. Lorincz AL (1985) Disturbances of Melanin Pigmentation. In: Moschella SL, Hurley HJ editors. *Dermatology Moschella and Hurley*, 2nd ed. Philadelphia: WS Saunders; p. 1290-317.

15. Dawber RP (1970) Integumentary associations of pernicious anaemia. *Br J Dermatol* 82: 221-223. [\[crossref\]](#)
16. Fatemi Naieni F, Ebrahimi B, Vakilian HR, Shahmoradi Z (2012) Serum iron, zinc, and copper concentration in premature graying of hair. *Biol Trace Elem Res* 146: 30-34. [\[crossref\]](#)
17. Wadhwa SL, Khopkar U, Nischal KC (2008) Hair and scalp disorders. In: Valia RG, Valia AR editors. *IADVL Textbook of Dermatology*. 3rd ed. Mumbai: Bhalani Publishing House; p. 864-948.
18. Balagula Y, Pulitzer MP, Maki RG, Myskowski PL (2011) Pigmentary changes in a patient treated with imatinib. *J Drugs Dermatol* 10: 1062-1066. [\[crossref\]](#)
19. Dalgic B, Egritas O (2011) Gray hair and acrodermatitis enteropathica-like dermatitis: an unexpected presentation of cystic fibrosis. *Eur J Pediatr* 170: 1305-1308. [\[crossref\]](#)
20. Trakymiene SS, Abla O (2010) Hodgkin lymphoma presenting with hair graying. *J Pediatr Hematol Oncol* 32: 417-418. [\[crossref\]](#)
21. Jo SJ, Paik SH, Choi JW, Lee JH, Cho S, et al. (2012) Hair graying pattern depends on gender, onset age and smoking habits. *Acta Derm Venereol* 92: 160-161. [\[crossref\]](#)
22. Reece AS (2007) Hair graying in substance addiction. *Arch Dermatol* 143: 116-118. [\[crossref\]](#)
23. Keogh EV, Walsh RJ (1965) Rate of greying of human hair. *Nature* 207: 877-878. [\[crossref\]](#)
24. Mosher DB, Fitzpatrick TB, Ortonne JP, Hori Y (1999) Hypomelanoses and hypermelanosis. Disorders of melanocytes. In: Freedberg IM, Eisen AZ, Katz SI, Wolff K, Goldsmith LA, Austen KF, et al. editors. *Fitzpatrick's Dermatology in General Medicine*. 5th ed. New York: McGraw Hill; p. 945-1017.
25. Findlay GH (1982) An optical study of human hair colour in normal and abnormal conditions. *Br J Dermatol* 107: 517-527. [\[crossref\]](#)
26. Messenger AG (1994) The control of hair growth and pigmentation. In: Olsen EA. editor. *Disorders of Hair Growth: Diagnosis and Treatment*. New York: McGraw-Hill; p. 39-58.
27. Hollfelder B, Blankenburg G, Wolfram LJ, Höcker H (1995) Chemical and physical properties of pigmented and non-pigmented hair ('grey hair'). *Int J Cosmet Sci* 17: 87-89. [\[crossref\]](#)
28. Choi HI, Choi GI, Kim EK, Choi YJ, Sohn KC, et al. (2011) Hair greying is associated with active hair growth. *Br J Dermatol* 165: 1183-1189. [\[crossref\]](#)
29. Gao T, Bedell A (2001) Ultraviolet damage on natural gray hair and its photoprotection. *J Cosmet Sci* 52: 103-118. [\[crossref\]](#)
30. Ruetsch SB, Kamath YK, Rele AS, Mohile RB (2001) Secondary ion mass spectrometric investigation of penetration of coconut and mineral oils into human hair fibers: relevance to hair damage. *J Cosmet Sci* 52: 169-184. [\[crossref\]](#)