

Case Report

Narrow-Band Imaging: A Novel Technique for Immediate Evaluation for The Efficacy of Laparoscopic Radiofrequency Ablation in Exophytic Hepatocellular Carcinoma

Mohamed Ismail Seleem¹, Mohamed Hassany¹, Nour abdelmaksoud Ali¹

¹Department of Surgery and Tropical Medicine, National Hepatology and Tropical Medicine Research Institute-Cairo-Egypt

Copyright: © 2017 Mohamed Ismail Seleem, et al. This is an open-access article distributed under the terms of the Creative Commons Attribution License, which permits unrestricted use, distribution, and reproduction in any medium, provided the original author and source are credited.

Abstract

Background: Intra-operative laparoscopic ultrasound (IOLUS) is the only modality one is able to use to evaluate the adequate ablation of Hepatocellular carcinoma (HCC) during surgery. We present the preliminary finding a novel use for narrow band imaging (NBI) in immediate detection of adequate ablation of exophytic HCC during laparoscopic radiofrequency ablation (LRFA).

Patients and Methods: The study was carried out in the Department of Hepato-Pancreatico-biliary Surgery at the National Hepatology and Tropical Medicine Research Institute (NHTMRI), Cairo, Egypt. Between September, 2010 and July, 2012, eleven patients with exophytic HCC were treated by laparoscopic radiofrequency ablation using intra-operative laparoscopic ultrasound (IOLUS) guidance. Evaluation of intraoperative ablation using IOLUS as well as NBI was recorded. Spiral CT scan one month postoperative was mandatory during follow up.

Results: 11 out of 50 patients with HCC, had an exophytic HCC. Evaluation of Intraoperative ablation using IOLUS as well as NBI showed complete ablation of the tumor in all patients which were proved and documented via spiral computed tomography (CT scan) one month post-operative.

Conclusion: Although only a few patients were studied there is persuasive evidence that NBI is able to provide a good idea in respect of the degree of exophytic HCC ablation. We feel that further evaluation of NBI in more patients will demonstrate the great value of this technique in the evaluation of degree of ablation of exophytic HCC.

Keyword: laparoscopy, exophytic HCC, narrow band imaging, liver cirrhosis.

Introduction

Hepatocellular carcinoma, the most common primary liver cancer, occurs in 90% of the cases in patients with chronic liver disease (CLD) [1]. In recent years, its incidence has increased as consequence of chronic hepatitis C virus infections [2]. LRFA appears to be safe procedures with low rates of morbidity and mortality [3]. The laparoscopic ultrasound permits more precise positioning of the radiofrequency needle multiple arrays near major blood vessels as well as the completion of tumor ablation. Narrow band imaging (NBI) is a technology of optical image enhancement which narrows the bandwidth of the light output from the Olympus Lucera laparoscopy system to 415nm and 540nm. This narrow bandwidth of light is strongly absorbed by hemoglobin and penetrates only the surface of tissue, increasing the visibility of capillaries and other delicate surface tissue structures by enhancing contrast between the two [4]. NBI is usually used in gastrointestinal endoscopy in detecting and predicating the histology of Barret's esophagus, [5] in the detection of urothelial cancer of the bladder [4] as well as squamous cell carcinomas in the head and neck [6] In this paper, we demonstrate a novel use for NBI in the immediate establishment of adequate ablation of exophytic HCC during LRFA.

Patients and Methods

A total of 11 patients with exophytic HCC were treated using LRFA between September, 2010 and July, 2012 at The National Hepatology and Tropical Medicine Research Institute-Cairo-Egypt.

All patients were submitted to diagnostic laparoscopy with intra-operative laparoscopic ultrasound (IOLUS) guidance. Evaluation of Intra-operative ablation using IOLUS as well as NBI was documented. A Spiral CT scan one month postoperative was an essential part of the protocol during follow up.

Laparoscopic Technique

The procedure was performed with the patient under general anaesthesia, intubated and placed in a supine position on the operating table. Laparoscopic exploration was performed with a zerodegree laparoscope. Another 10mm port was placed according to the location of the HCC, with an addition 5mm port. Laparoscopic ultrasound of the entire liver was carried out followed by localization of HCC using white light imaging (WLI) (Figure 1b & 2b). The vital organs near HCC were protected (Figure 1b). The HCC was inspected using NBI (Figure 1c & 2c). RFA was performed under ultrasonographic guidance, utilizing a generator providing 460 kHz alternating current and semi-flex retractable multi-pronged curved electrode-needles (RITA medical system, Mountain View, California). The average target temperature was set at 100°C to 110 °C, and ablation

***Corresponding author:** Mohamed Ismail Seleem, Department of Surgery and Tropical Medicine, National Hepatology and Tropical Medicine Research Institute, 11, Mo-Ezz El-Dawlah street -off, Makram Obeid Street, Nasr City, Cairo- Egypt, Tel: +201113447442; Fax: +201113447442; E-mail: saleem_1961@hotmail.com

Received: January 13, 2017; **Accepted:** January 23, 2017; **Published:** January 27, 2017

was continued for 25-30 minutes depending on the desired ablation size (3-5 cm in diameter). The process was monitored by real-time ultrasound to ensure ablation. Thereafter, the HCC was inspected using NBI (Figure 1d&e & Figure 2d, e&f) as well as WLI (Figure 2g).

A triphasic CT scan was obtained one month post-operatively to prove and compare the intra-operative and post-operative finding.

Results

11 out of 50 patients with HCC, had an exophytic HCC. Evaluation of Intra-operative ablation of HCC using IOLUS as well as NBI as described, and shown in (Figure 1&2) the HCC was evaluated by laparoscopy using WLI (Figure 1b & 2b) and NBI (Figure 1c & 2c). Before ablation, the tumor appears bluish or dark green in color. However, after complete ablation it appears red in color since there was no hemoglobin present on account of the fact that the tumor is well ablated and the superficial blood capillaries were coagulated (Figure 1e & 2f). NBI reveal incomplete ablation of the tumor in case number two (Figure 2d) which required re-position of the radiofrequency needle to reach full tumor ablation (Figure 2e). All patients requested to have spiral computed tomography (CT scan) one month post-operatively in every case to prove and document complete ablation of the tumor (Figure 1f & 2h).

Discussion

There are many reports in the literature on the use of NBI in various regions of the body. Hamamoto et al. [7] evaluated the usefulness of NBI in diagnosis of Barrett's oesophagus. The value of

NBI in detection of high grade dysplasia and early cancer in Barrett's oesophagus was evaluated by Kara et al. [8] Uedo et al. [9] investigated the use of NBI for detection of intestinal metaplasia in gastric mucosa with the sensitivity 89% and a specificity of 93%. Uchiyama et al. [10] investigated the reliability of NBI to diagnosis and differentiate between benign and malignant duodenal ampullary tumours concluding that there is a great potential for foci of adenocarcinoma which escaped detection with forceps biopsy to be diagnosed accurately diagnosed by NBI. Machida et al. [11], studied the use of NBI for evaluating colorectal lesions and found that in the examination of colonic lesions the NBI system provides additional imaging features to augment those obtained both with conventional endoscopy. A further investigation was reported by Su et al. [12] comparing conventional colonoscopy and NBI in the differential diagnosis of neoplastic and non-neoplastic colonic polyps.

Our study is first to be published in respect of the use of NBI in laparoscopic surgery. Laparoscopy provides a much better view of an exophytic HCC tumour during laparoscopic radiofrequency ablation treatment. The hypervascular exophytic HCC, appear dark green or blue in color during the use of NBI while the ablated exophytic tumour appear red in color against the almost dark green or blue of surrounding liver tissue during the use of NBI (figure 2f). This is particularly noticeable during the LRFA of exophytic HCC which is difficult to detect with the conventional white light image (Figure 1b & 2g).

In conclusion, our experience shows that NBI not only improves the detection of, but additionally, aids the complete ablation of

Figure 1a: CT scan arterial phase, arrow pointed to HCC segment V.

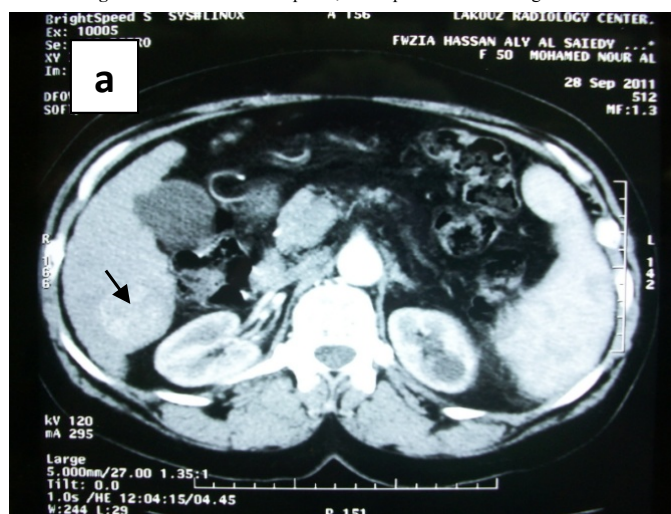

Figure 1b: Laparoscopic view of HCC using WLI.

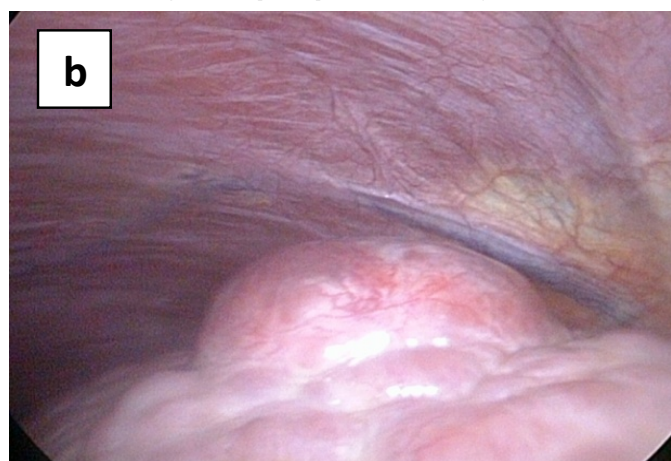

Figure 2 a: CT scan arterial phase, arrow pointed to HCC segment VIII.

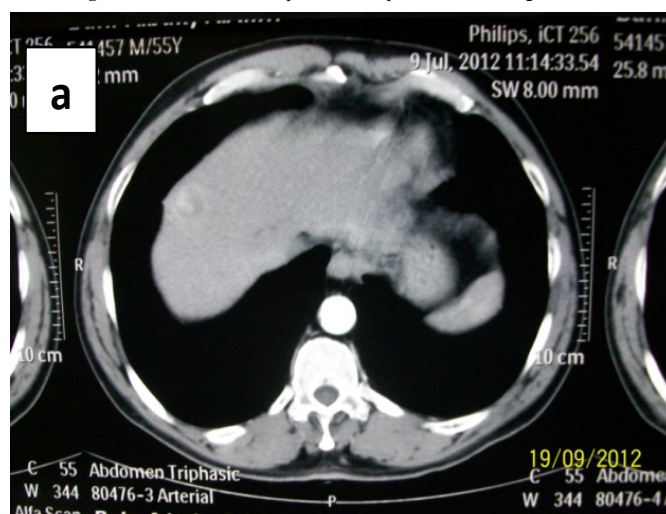


Figure 2 b: Laparoscopic view of HCC using WLI.

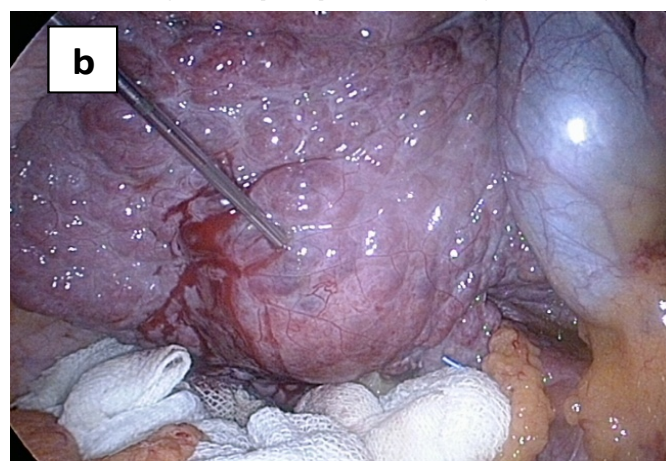


Figure 1c: Laparoscopic view of HCC using NBI (blue or dark green color).

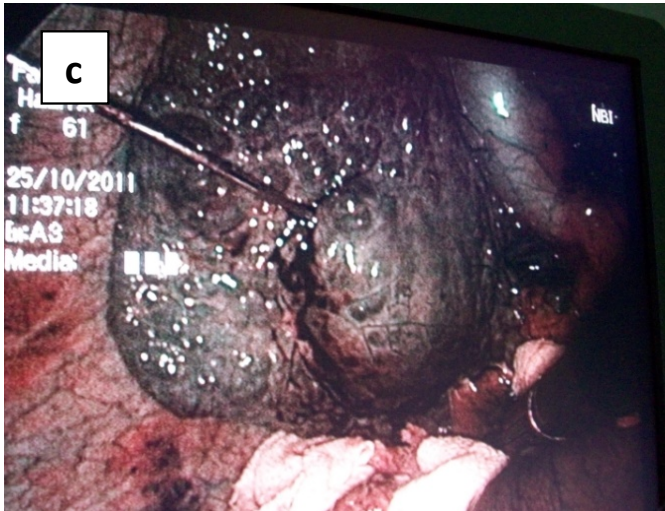

Figure 2c: Laparoscopic view of HCC using NBI (blue or dark green color).

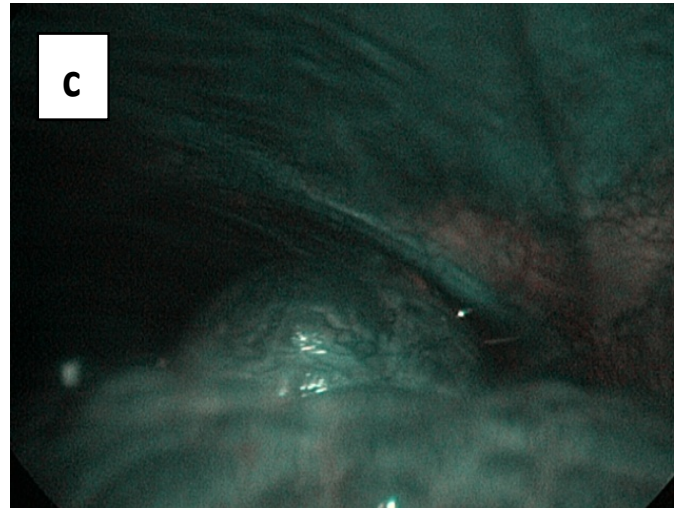


Figure 1e: Laparoscopic view of HCC reveal complete ablation (red color).

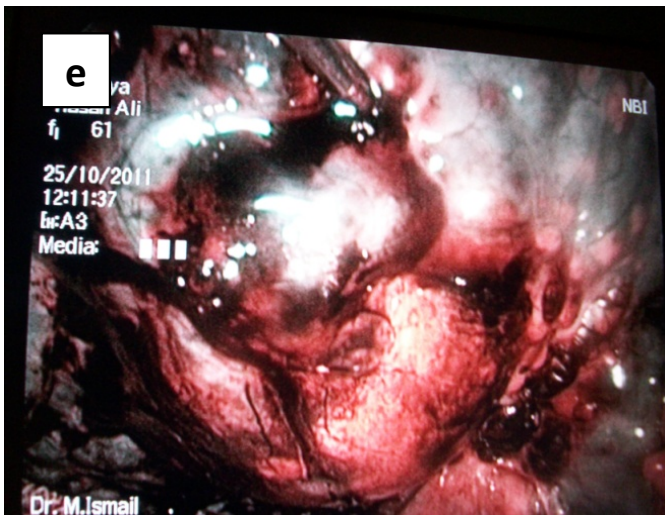

Figure 2f: Laparoscopic view of HCC reveal complete ablation by NBI.

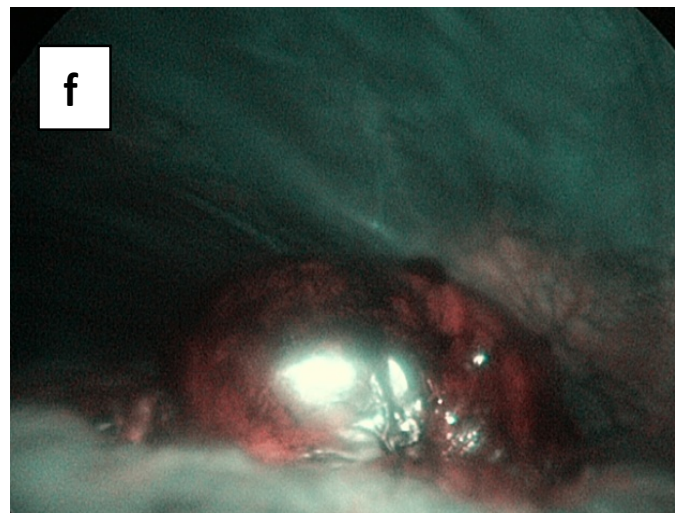


Figure 2d: Laparoscopic view of HCC using NBI showing incomplete ablation.

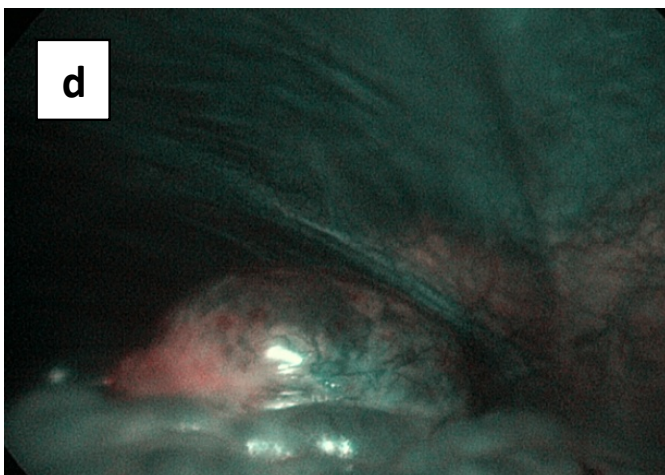


Figure 2e: Laparoscopic view show re-position of radiofrequency needle.

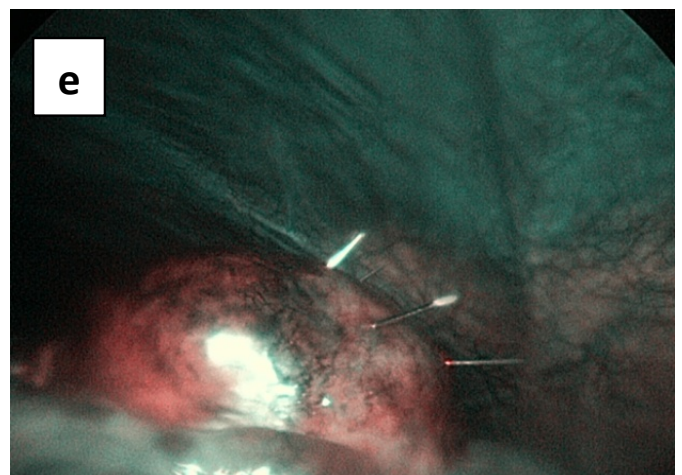


Figure 1f: CT scan arterial phase, arrow pointed to complete ablated area.

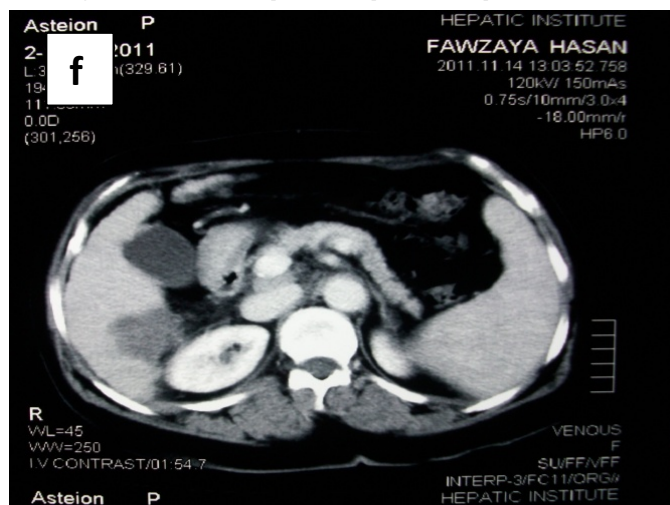


Figure 2 h: CT scan arterial phase, arrow pointed to complete ablated area.

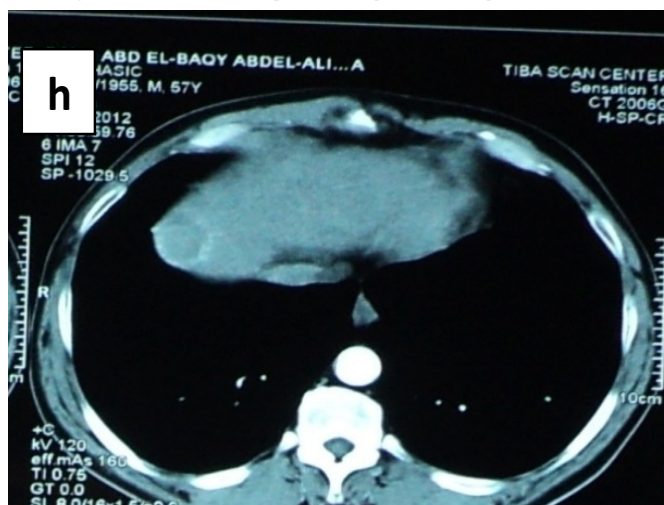


Figure 1b: Laparoscopic view of HCC using WLI.

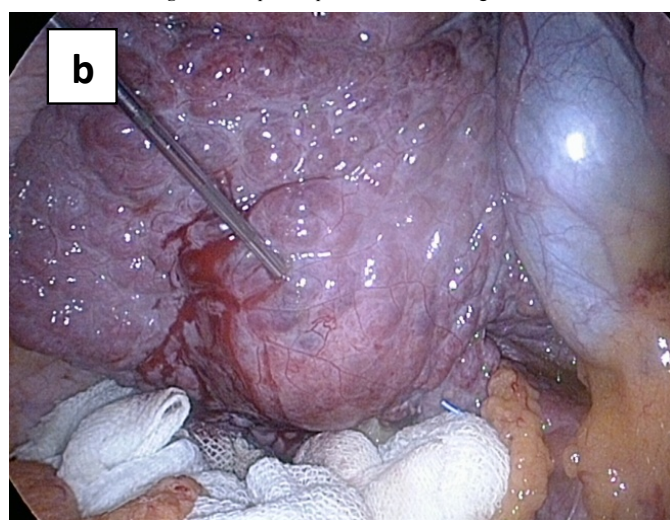
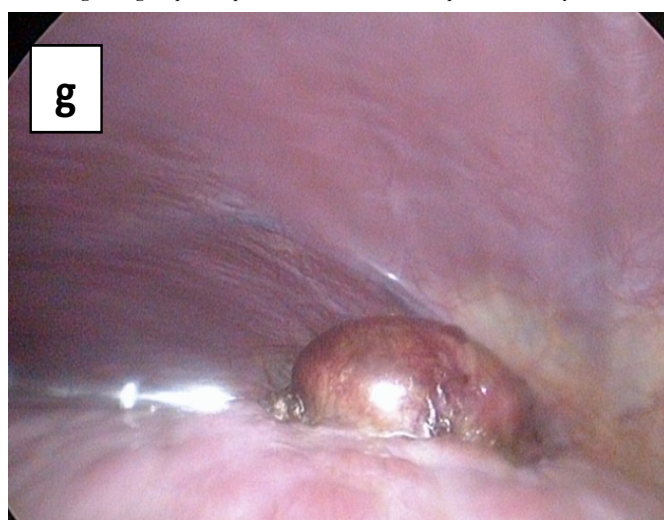


Figure 2 g: Laparoscopic view of HCC reveal complete ablation by WLI.



exophytic HCC and this has been confirmed by IOLUS and post-operative triphasic CT scan.

References

- Llovet JM, Burroughs A, Bruix J (2003) Hepatocellular carcinoma. *Lancet* 362: 1907-1917. [\[crossref\]](#)
- Deuffic S, Poynard T, Buffat L, Valleron AJ (1998) Trends in primary liver cancer. *Lancet* 351: 214-215. [\[crossref\]](#)
- Seleem MI, Gerges SS, Elkhoully AA, El-wakeel BA, Barbary MH, et al. (2012) Laparoscopic radiofrequency thermal ablation of hepatocellular carcinoma in liver cirrhosis patients. *Gastroenterology Research J* 5:232-235.
- Richard T Bryan, Lucinda J Billingham, D Michael A Wallace (2008) Narrow-band imaging flexible cystoscopy in the detection of recurrent urothelial cancer the bladder. *BJU Int* 101: 702-706.
- Sharma P, Bansal A, Mathur S et al. (2006) The utility of a novel narrow band imaging endoscopy system in patients with Barrett's esophagus. *Gastrointest Endosc* 64: 167-175.
- Piazza C, Dessoukyi O, Peretti G, et al. (2008) Narrow-band imaging: a new tool for evaluation of head and neck squamous cell carcinomas. Review of the literature. *ACTA otorhinolaryngologica italica* 28:49-54.
- Hamamoto Y, Endo T, Noshio K, Arimura Y, Sato M, et al. (2004) Usefulness of narrow-band imaging endoscopy for diagnosis of Barrett's esophagus. *J Gastroenterol* 39: 14-20. [\[crossref\]](#)
- Kara MA, Peters FP, Rsumolen WD, Krishnadath KK, Ten Kate FJW, et al. (2005) High-resolution endoscopy plus chromoendoscopy or narrow-band imaging in Barrett's esophagus: a prospective randomized crossover study. *Endoscopy* 37: 926-936.
- Uedo N, Ishihara R, Iishi H, Yamamoto S, Yamada T, et al. (2006) A new method of diagnosing gastric intestinal metaplasia: narrow-band imaging with magnifying endoscopy. *Endoscopy* 38: 819-824.
- Uchiyama Y, Imazu H, KaKutani H, Hino S, Sumiyama K, et al. (2006) New approach to diagnosing ampullary tumors by magnifying endoscopy combined with a narrow-band imaging system. *J Gastroenterol* 41: 483-490.
- Machida H, Sano Y, Hamamoto Y, Muto M, Kozu T, et al. (2004) Narrow-band imaging in the diagnosis of colorectal mucosal lesions: a pilot study. *Endoscopy* 36: 1094-1098. [\[crossref\]](#)
- Su MY, Hsu CM, Ho YP, Chen PC, Lin CJ, et al. (2006) Comparative study of conventional colonoscopy, chromoendoscopy, and narrow-band imaging systems in differential diagnosis of neoplastic and nonneoplastic colonic polyps. *Am J Gastroenterol* 101: 2711-2716. [\[crossref\]](#)