

## Case Report

# Intraoperative Iliac Crest Intraosseous Line Placement as A Rescue Maneuver: A Case Report

Ahmed M. Meleis<sup>1</sup>, Aria Mahtabfar<sup>2</sup>, Shri Srinivasan<sup>1</sup>, Antonios Mammis<sup>1</sup><sup>1</sup> Department of Neurological Surgery, Rutgers, The State University of New Jersey- RBHS - New Jersey Medical School, 90 Bergen Street, Suite 8100, Newark, NJ, 07103, USA<sup>2</sup> Rutgers, The State University of New Jersey – RBHS - Robert Wood Johnson Medical School, Rutgers–New Brunswick, 675 Hoes Ln W, Piscataway Township, NJ 08854, USA**Copyright:** © 2016 Ahmed M Meleis, et al. This is an open-access article distributed under the terms of the Creative Commons Attribution License, which permits unrestricted use, distribution, and reproduction in any medium, provided the original author and source are credited.

## Abstract

Peripheral venous access is often lost intraoperatively. Reestablishing access may be difficult and futile, and poses an emergency in the setting of hemodynamic instability. When appropriate, the use of intraosseous access should be considered as a salvage maneuver given the function of bone marrow as a noncollapsible venous access route. In this report, we describe a novel technique using the Jamshidi needle to access iliac crest bone marrow during a case of posterior cervical decompression and fusion where peripheral venous access was lost intraoperatively and unable to be reestablished. This technique may provide recourse during future operative settings needing rapid access to a noncollapsible vein.

**Key Words:** *Intraosseous; Iliac crest; Intraoperative venous access*

## Introduction

The idea of intraosseous vascular access was first introduced in 1922 by Drinker and colleagues as a method for accessing noncollapsible venous plexuses through the bone marrow cavity to systemic circulation. Specifically, Drinker et al. described the concept of using the circulation of the sternum and suggested it be used for a route for blood transfusion. The method was abandoned with the development of intravenous (IV) catheters until the 1980s, when intraosseous access was reintroduced, particularly for rapid fluid infusion during resuscitation [1]. There are several published articles that have described the use of intraosseous access in military and rescue scenarios, where rapid access may be crucial and peripheral venous access may be hard to obtain. Furthermore, the Emergency Cardiovascular Care Guidelines in 2000 recommended intraosseous access use in all children after two failed attempts at IV access or during circulatory collapse. In 2005, the American Heart Association recommended intraosseous access if venous access cannot be quickly and reliably established [2]. In our report, we describe a novel technique not described before where we use the Jamshidi needle that was used for iliac crest bone marrow aspirate as an IV access point for volume resuscitation in a patient where a peripheral IV access was lost. The Jamshidi needle, remaining placed in the bone marrow after obtaining aspirate, was connected to an IV line and used as a new IV access point.

## Procedure

The surgery described was a posterior cervical decompression and fusion for cervical spine stenosis. The patient was brought back to operating room where anesthesia obtained 1 peripheral IV access point prior to intubation, and then a second one after intubation. A radial artery arterial line was then placed. The patient was put in Mayfield pins and flipped prone with the arms tucked to the side and the patients head secured onto the Mayfield head holder. Once the patient was secured, the cervical spine was prepped, and the posterior superior iliac crest was palpated on both hips and marked for preparation for bone marrow aspirate. The entire area of prepped and

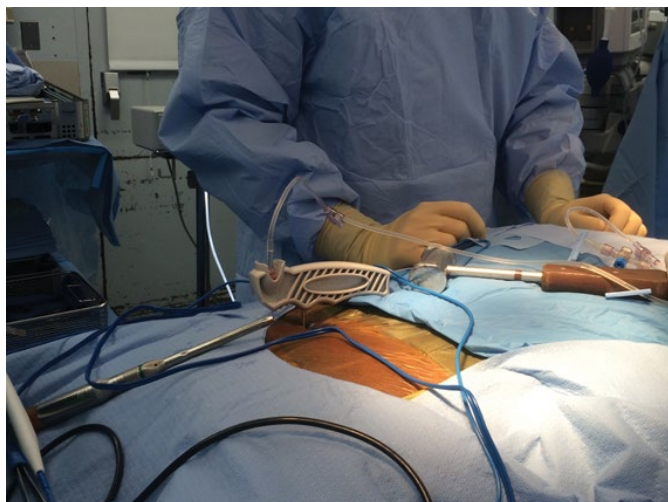
draped. Once we finished draping, anesthesia noted that one of the patient's IV access had stopped running. Because of the positioning of the patient's arms, it was difficult for them place an IV in the hands or arms. Anesthesia attempted to place IV access in the foot as well. During this time however, the patient started to become hypotensive due to a lack of IV fluids. With the patient's blood pressure dropping, peripheral IV access becoming an issue, and patient positioning making central line access difficult, it was discussed trying to obtain interosseous access. At this junction, we went ahead and used a 15 blade to make a stab incision over where we palpated the PSIS and then Jamshidi needle down until we palpated bone with the needle. We hammered the Jamshidi needle into the bone marrow using a mallet and obtained 15ml of bone marrow. Once that was done, we connected the IV line to the outer cannula of the Jamshidi that was anchored into the bone marrow (Figure 1). IV fluid was confirmed to be running through the line into the bone marrow space. The patient's blood pressure began to respond to the IV fluids and was adequately resuscitated. At this junction we left the IV line and Jamshidi in place and continued the case with no further issues. Intraoperatively and post-operatively the patient was noted to be doing well and kidney function, as well as urine output, was appropriate and stable.

## Conclusion

The marrow of long bones has a rich network of vessels that drain into a central venous canal, emissary veins, and, ultimately, the central circulation. Therefore, the bone marrow functions as a noncollapsible venous access route when peripheral veins may have collapsed because of vasoconstriction. This approach is particularly important in patients in shock or cardiac arrest, when blood is

\*Corresponding author: Ahmed M Meleis, Department of Neurological Surgery, Rutgers, The State University of New Jersey- RBHS - New Jersey Medical School, 90 Bergen Street, Suite 8100, Newark, NJ, 07103, USA, Tel: 732-673-5668; Fax: 732-673-5668; E-mail: meleisah@njms.rutgers.edu

Received: March 31; Accepted: April 27, 2016; Published: May 01, 2016



**Figure 1:** The Jamshidi cannula in the posterior superior iliac spine with the IV line connected and running.

shunted to the core due to compensatory peripheral vasoconstriction [1]. The intraosseous route allows medications and fluids to enter the central circulation within seconds. In this case report, we describe a novel method intraoperatively to use the concept of intraosseous access as a potentially salvage maneuver when performing surgery

where peripheral IV access is lost and re-establishing new IV access may be difficult. One consideration and/or complication one must keep in mind is extravasation of blood or infusion into surrounding soft tissue from poor technique or prolonged infusion. In our institution, there have been various issues with IV access during cervical spinal surgery on prone patients with the arms tucked to the side. This has included: kinked IV's, leaking IV's, and IV's lines that have been pulled out. This has led to increased OR time until the IV lines were fixed, and in one case a patient waking up from anesthesia in the middle of the procedure. This method of using the Jamshidi cannula allows direct visualization of the IV and confirmation that the IV is not kinked or leaking, and can act as a rescue maneuver to allow the operative case to continue without complications.

#### **Conflict of Interest**

The authors declare no conflict of interest.

#### **References**

1. Bohn D (1999) Intraosseous vascular access: from the archives to the ABC. *Crit Care Med* 27: 1053-1054. [\[crossref\]](#)
2. American Heart Association (2006) 2005 American Heart Association (AHA) guidelines for cardiopulmonary resuscitation (CPR) and emergency cardiovascular care (ECC) of pediatric and neonatal patients: pediatric basic life support. *Pediatrics* 117: e989-1004. [\[crossref\]](#)